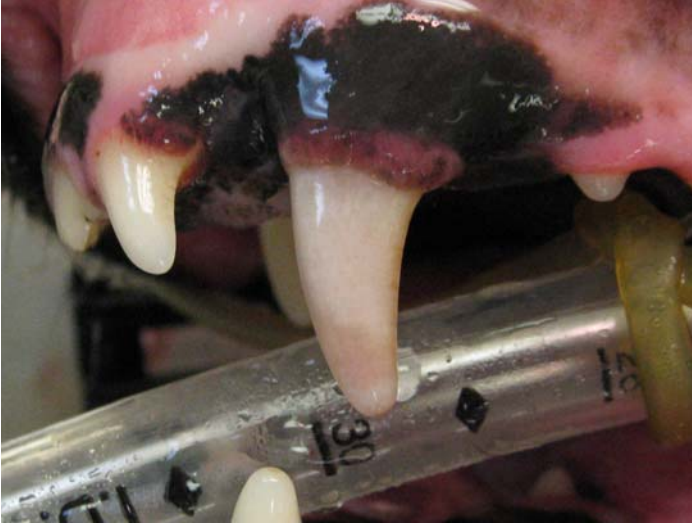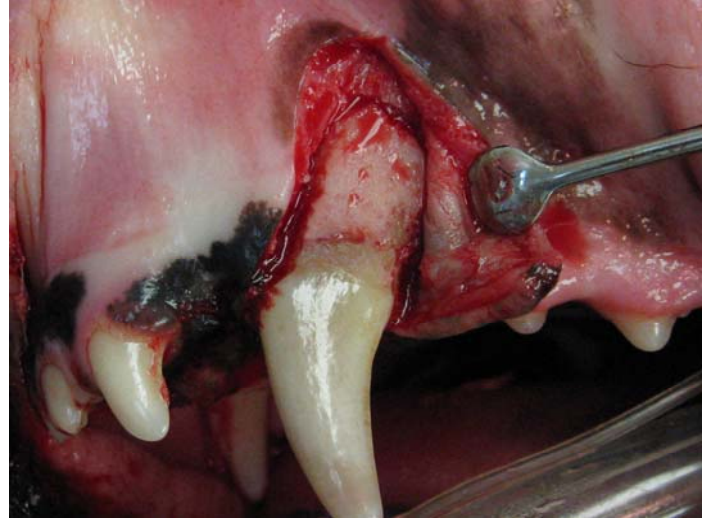


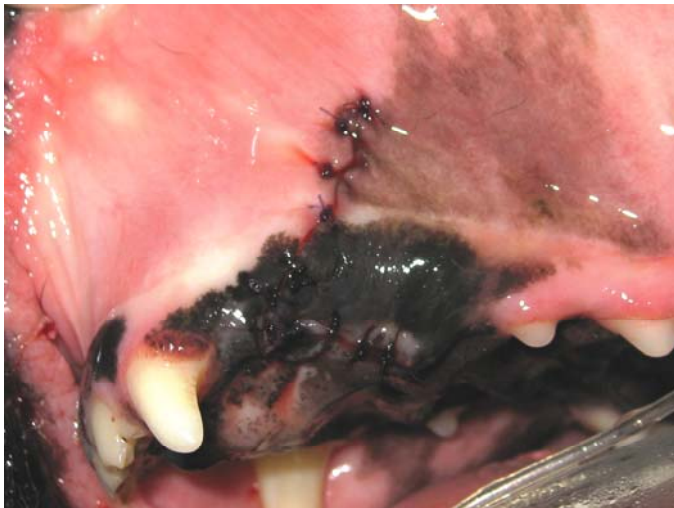Surgical Extraction of a Maxillary Canine Tooth



The photo shows the devitalized maxillary canine tooth that will be extracted.



A full thickness flap was created by making a single buccal incision over the mesial surface of the root. A #2 round bur on a high speed handpiece was used cut the buccal bone over the mesial and distal surfaces of the root. A third cut was made through the bone on the buccal surface of the root. Elevators were used to gently extract the tooth.



The flap was closed without any tension using an absorbable, monofilament suture material.

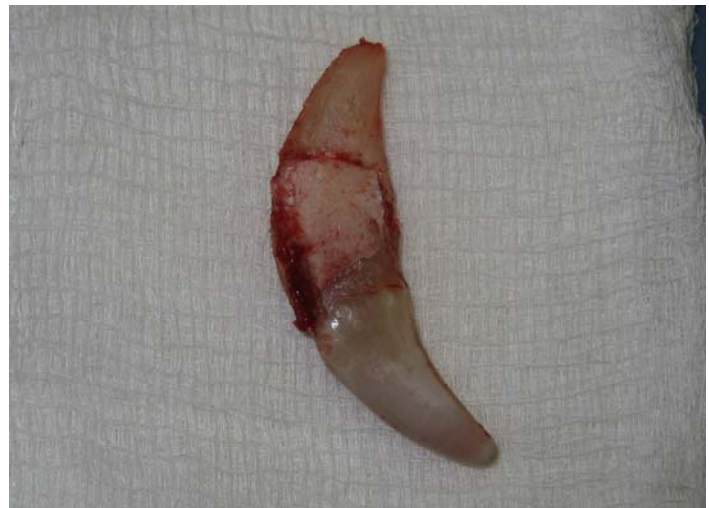

Photo of the extracted tooth.