

Case of the Month

October 2007

History and Signalment

A two year old Bichon Frise presented for a routine periodontal evaluation and treatment. Aside from the minimal calculus and gingivitis discovered, the left and right mandibular permanent 1st incisors were missing.

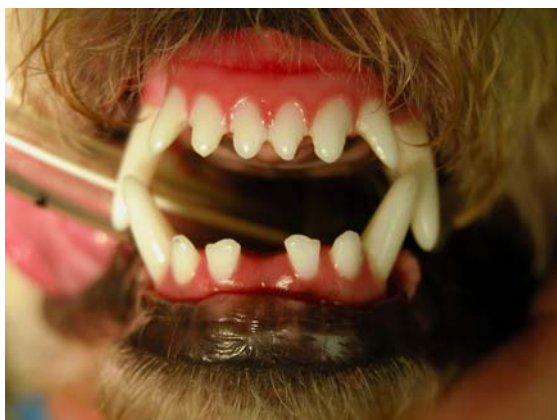
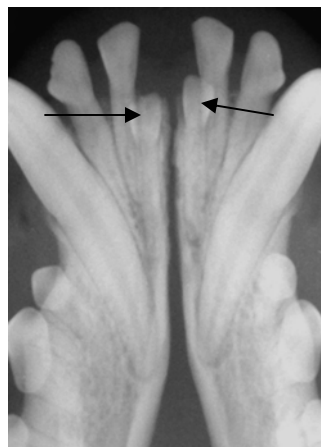
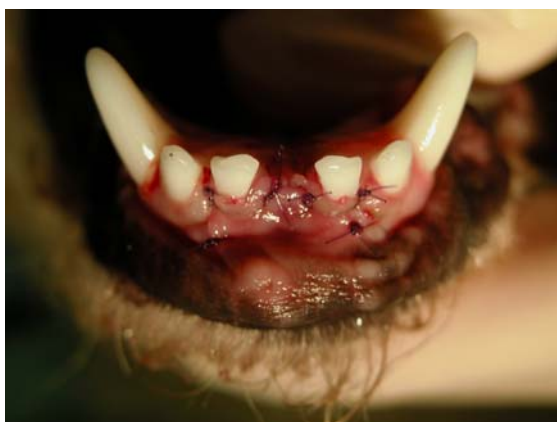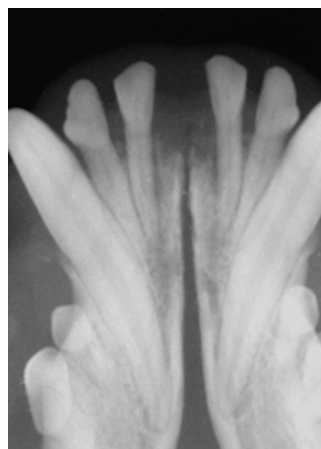
Photo showing the missing 1st mandibular incisors.



Intraoral radiographs show the missing incisors.



The flap used to access the impacted teeth was sutured closed.



Post extraction radiograph.

Treatment

Intraoral radiographs were taken showing the impacted teeth. A gingival flap was created to allow access to the teeth. The teeth were carefully elevated without damaging the adjacent roots. The flap was sutured closed with absorbable suture material.

Early diagnosis and treatment of missing teeth is very important. Often, the unerupted teeth are not seen on radiographs and require no treatment. Failure to diagnose missing teeth can lead to very serious dental problems.

Veterinary Dental Center of Tulsa
4820 E. 33rd Street
Tulsa, OK 74135
(918) 749-8387
David S. Russell, DVM
Fellow, Academy of Veterinary