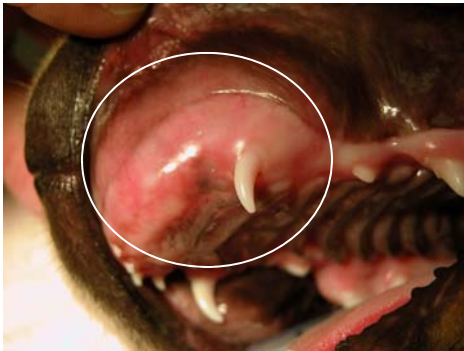

Case of the Month

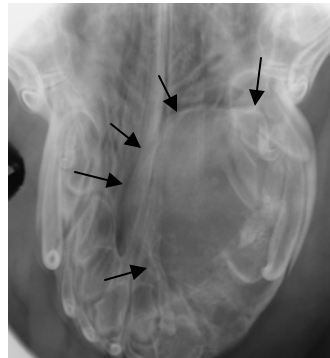
September 2007

History and Signalment

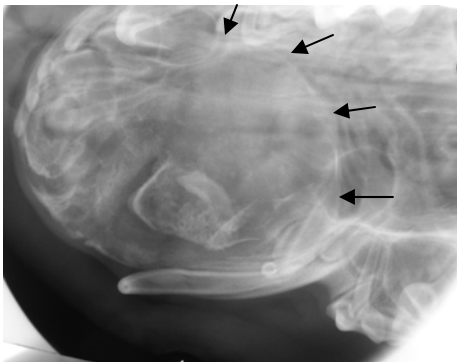
A 9 week old Labrador Retriever presented for a painful swelling on the left side of his muzzle. The swelling was noticed two weeks before presentation. Some of the dog's deciduous teeth were missing and the left maxillary canine tooth erupted much later than the right.



The circle area was swollen. Notice the missing incisors.



The radiograph shows the outline of the swelling.



A left lateral radiograph showing a different view of the swelling.

Treatment

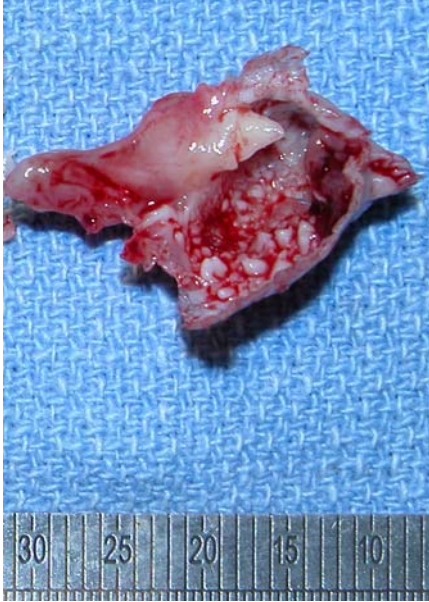The mass was excised and submitted for histopathology.

Based on the history and radiographs, what is the diagnosis?

Veterinary Dental Center of Tulsa
4820 E. 33rd Street
Tulsa, OK 74135
(918) 749-8387
David S. Russell, DVM
Fellow, Academy of Veterinary
Dentistry

Diagnosis

A diagnosis of a compound odontoma was verified with histopathology. A compound odontoma is a benign tumor that develops from an inductive effect between the epithelial and mesenchymal tissues. It is a process similar to what happens during tooth formation. Surgical excision of the mass is usually curative.



This section of the excised mass shows the numerous tooth-like structures (denticles).

Veterinary Dental Center of Tulsa
4820 E. 33rd Street
Tulsa, OK 74135
(918) 749-8387
David S. Russell, DVM
Fellow, Academy of Veterinary
Dentistry